

# 超声骨刀行后路单开门椎管成形术治疗多节段脊髓型颈椎病并部分颈椎不稳

何贻强, 苟小力, 陈扬帆, 袁家钦, 李波

重庆医科大学附属永川医院脊柱外科, 重庆 402160

**摘要:** **目的** 评价在多节段脊髓型颈椎病(MCSM)并部分颈椎不稳患者用超声骨刀行后路单开门椎管成形术的效果观察。**方法** 2017年6月至2018年5月收治MCSM并部分颈椎不稳患者共32例,行超声骨刀行后路单开门椎管成形术。记录手术时间。随访症状、体征及神经功能恢复并记录。术前、术后及随访时JOA评分评估脊髓功能。X线片及CT复查评估颈椎曲度、稳定性、内固定位置及椎管扩大情况。对于颈椎后凸病例的颈椎曲度采用颈椎 $C_2 \sim C_7$ 夹角(CSA)评估恢复情况。**结果** 患者均如期完成手术。手术时间 $90 \sim 210(144.00 \pm 49.50)$  min。术后随访时间 $8 \sim 15(14.80 \pm 2.12)$ 个月。术后X线片及CT检查显示合并颈椎后凸患者颈椎曲度恢复良好。所有患者无断钉、断棒及颈椎不稳定。CT检查显示螺钉位置良好,椎管扩大成形术疗效满意,术后随访无再关门及门轴断裂。JOA评分术前 $(6.47 \pm 1.41)$ 分,术后1周 $(7.50 \pm 1.51)$ 分,末次随访 $(10.75 \pm 1.54)$ 分,术后1周和末次随访时JOA评分均高于术前,末次随访时JOA评分均高于术后1周,差异有统计学意义( $P < 0.01$ )。合并颈椎后凸的10例患者颈椎曲度评估,CSA术前 $(-10.70 \pm 1.54)^\circ$ ,术后1周 $(17.20 \pm 1.07)^\circ$ ,末次随访 $(17.60 \pm 1.25)^\circ$ ,术后1周和末次随访时CSA均优于术前,差异有统计学意义( $P < 0.01$ );术后1周和末次随访时比较无统计学差异( $P > 0.05$ )。**结论** 超声骨刀应用于后路单开门椎管成形术治疗MCSM是一种安全、有效的方法。有利于颈椎曲度的恢复,维持颈椎良好稳定性。

**关键词:** 多节段脊髓型颈椎病; 超声骨刀; 单开门椎管扩大成形术, 后路; 颈椎曲度

**中图分类号:** R 681.5 **文献标志码:** B **文章编号:** 1674-8182(2020)06-0818-04

## Single open door laminoplasty with ultrasonic scalpel in the treatment of cervical spondylotic myelopathy with partial cervical instability

HE Yi-qiang, GOU Xiao-li, CHEN Yang-fan, YUAN Jia-qin, LI Bo

Department of Spinal Surgery, Yongchuan Hospital of Chongqing Medical University, Chongqing 402160, China

Corresponding author: LI Bo, E-mail: cqeylibo@163.com

**Abstract: Objective** To evaluate the effect of open-door laminoplasty with ultrasonic scalpel in the treatment of multisegmental cervical spondylosis (MCSM) and cervical instability. **Methods** A total of 32 patients with MCSM and partial cervical instability were treated with single open door laminoplasty from June 2017 to May 2018. The operation time was recorded. The symptoms, signs and neurological function were recovered and recorded. JOA score was used to evaluate spinal cord function before, after and during follow-up. X-ray and CT Reexamination were used to evaluate cervical curvature, stability, internal fixation position and spinal canal enlargement. The recovery of cervical curvature in kyphosis was evaluated by the angle between  $C_2$  to  $C_7$  (CSA). **Results** All patients completed the operation as scheduled. The operation time was  $90 - 210 (144.00 \pm 49.50)$  min. The follow-up time was  $8 - 15 (14.80 \pm 2.12)$  months. The postoperative X-ray and CT examination showed that the curvature of cervical spine recovered well in patients with kyphosis. All patients had no broken nail, broken rod or cervical instability. CT showed that the screw position was good and the effect of laminoplasty was satisfactory. JOA score was  $6.47 \pm 1.41$  before operation,  $7.50 \pm 1.51$  one week after operation, and  $10.75 \pm 1.54$  at the last follow-up. JOA score was higher at the first week and the last follow-up than before operation, and it was higher at the last follow-up than one week after operation ( $P < 0.01$ ). The evaluation of cervical curvature in 10 patients with kyphosis was  $-10.70^\circ \pm 1.54^\circ$  before the operation,  $17.20^\circ \pm 1.07^\circ$  after the operation, and  $17.60^\circ \pm 1.25^\circ$  at the last follow-up. CSA was superior to that before the operation in 1 week and at the last follow-up

( $P < 0.01$ ). There was no significant difference between the first week and the last follow-up ( $P > 0.05$ ). **Conclusion**

Ultrasound osteotomy is a safe and effective method in the treatment of MCSM. It is beneficial to the recovery of cervical curvature and the maintenance of good stability of cervical spine.

**Key words:** Multi-segmental cervical spondylosis; Ultrasound osteotome; Single open door laminoplasty; Posterior approach; Cervical curvature

超声骨刀是脊柱外科一种新的截骨工具,其设计理念超声频率下的微振动来进行截骨。其优点是选择性切骨,降低对相邻软组织破坏的风险,已经广泛用于口腔和颌面外科领域<sup>[1-2]</sup>。但在多节段脊髓型颈椎病(multilevel cervical spondylotic myelopathy, MCSM)未见相关报道,本研究旨在评价超声骨刀在后路单开门 MCSM 手术中的应用。

## 1 资料与方法

**1.1 一般资料** 2017 年 6 月至 2018 年 5 月收治 MCSM 并部分颈椎失稳患者共 32 例,其中男性 19 例,女性 13 例;年龄 51 ~ 73 ( $64.70 \pm 6.65$ ) 岁。术前均已完善颈椎正侧位和动力位 X 线片、颈椎 MRI、颈椎 CT 血管造影、颈椎 CT + 三维成像处理。所有病例均未发现颈椎椎弓根缺如及严重狭窄,未发现椎动脉变异。合并颈椎曲度变直 12 例,颈椎后凸 10 例。术前患者脊髓神经功能日本骨科学会(Japanese Orthopaedics Association, JOA)评分( $6.47 \pm 1.41$ )分。纳入标准:(1)颈椎椎管狭窄的节段均  $\geq 3$  个;(2)有脊髓长束受压的临床表现,如细小动作失灵、步态不稳、四肢腱反射亢进、肌张力增高;(3)伴有颈椎失稳。排除标准:(1)合并颈椎严重后凸畸形;(2)颈椎间盘脱出游离患者;(3)合并椎动脉发育畸形或颈椎椎弓根发育异常,合并重度骨质疏松;(4)椎间孔狭窄、前方致压物大于 7 mm 或椎管侵占率  $\geq 60\%$ <sup>[3]</sup>。

**1.2 手术方法** 全身麻醉及气管插管,取俯卧位,手术头架固定,使颈部前屈位,用宽胶带固定双肩使其向尾端。后正中切口,显露 C<sub>2</sub> ~ C<sub>7</sub> 棘突及两侧椎板。术中使用超声骨刀选择相应减压节段,铰链侧为症状轻侧,开门侧椎板掀起后棘突固定于铰链侧小关节囊上。对于颈椎曲度变直或正常的病例,椎弓根钉置入至相应节段的颈椎椎弓根内固定。对于颈椎后凸的病例,置入椎弓根螺钉至 C<sub>2</sub>、C<sub>4</sub>、C<sub>6</sub> 或 C<sub>3</sub>、C<sub>5</sub>、C<sub>7</sub> 椎体内。棒预弯成正常弧度后连接并固定于螺钉上。取自体髂骨或同种异体骨植于铰链侧椎板缝隙处。术后 3 d,指导患者可在颈托固定下活动,并逐步加大活动量。术后预防感染及消肿处理。

**1.3 术后观察及随访指标** 术后记录手术时间。随访症状、体征及神经功能恢复并记录。术前、术后及

随访时 JOA 评分并计算改善率评估脊髓功能。X 线片及 CT 复查评估颈椎曲度、稳定性、内固定位置及椎管扩大情况。对于颈椎后凸病例的颈椎曲度采用颈椎 C<sub>2</sub> ~ C<sub>7</sub> 夹角(CSA)评估恢复情况。

**1.4 统计学方法** 采用 SPSS 20.0 软件进行统计分析。计量资料以  $\bar{x} \pm s$  表示,术前术后对比采用 SNK-*q* 法。 $P < 0.05$  为差异有统计学意义。

## 2 结果

**2.1 一般情况** 患者均如期完成手术。手术时间 90 ~ 210 ( $144.00 \pm 49.50$ ) min。1 例出现伤口感染,积极抗生素治疗好转后出院。未发现严重并发症如脑脊液漏及脊髓损伤等。术后随访时间 8 ~ 15 ( $14.80 \pm 2.12$ ) 个月。术后 X 线片及 CT 检查显示合并颈椎后凸患者颈椎曲度恢复良好。所有患者无断钉、断棒及颈椎不稳定。CT 检查显示螺钉位置良好,椎管扩大成形术疗效满意,术后随访无再关门及门轴断裂。

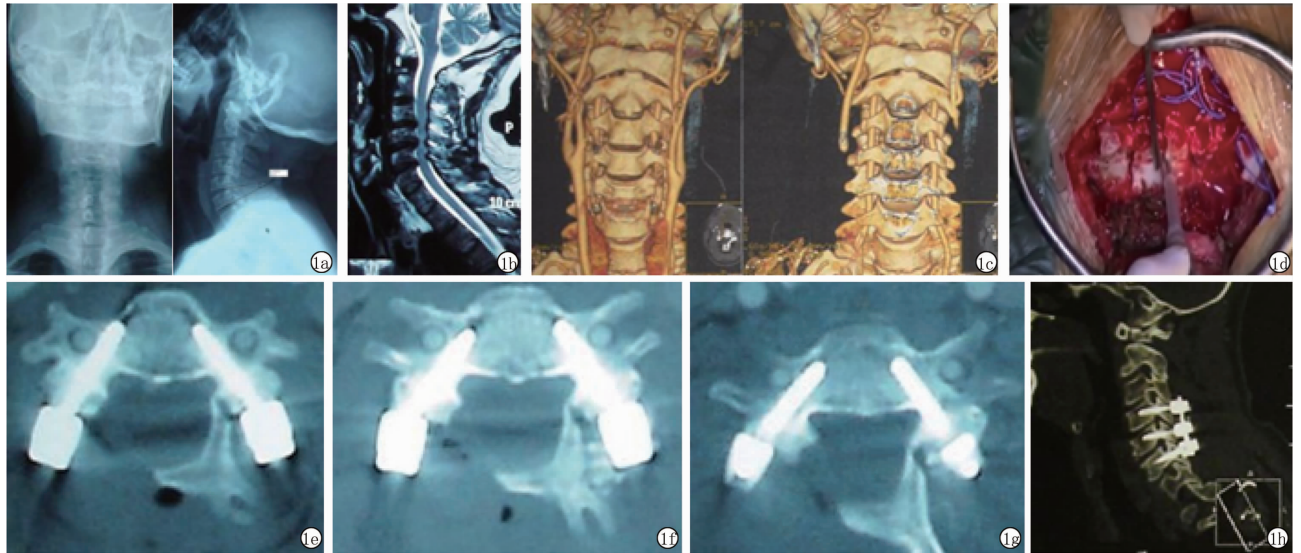
**2.2 JOA 评分** JOA 评分术前( $6.47 \pm 1.41$ )分,术后 1 周( $7.50 \pm 1.51$ )分,末次随访( $10.75 \pm 1.54$ )分,术后 1 周和末次随访时 JOA 评分均高于术前,末次随访时 JOA 评分均高于术后 1 周,差异有统计学意义( $P < 0.01$ )。

**2.3 颈椎曲度评估** 合并颈椎后凸的 10 例患者颈椎曲度评估,CSA 术前( $-10.70 \pm 1.54$ )°,术后 1 周( $17.20 \pm 1.07$ )°,末次随访( $17.60 \pm 1.25$ )°,术后 1 周和末次随访时 CSA 均优于术前,差异有统计学意义( $P < 0.01$ );术后 1 周和末次随访时比较无统计学差异( $P > 0.05$ )。

**2.4 典型病例** 男性患者,52 岁,MCSM 伴颈椎失稳的典型病例 X 线片、MRI、CTA、术中图片及术后 CT 图。见图 1。

## 3 讨论

自后路单开门颈椎椎板成形术开展以来,颈椎后路单开门椎管扩大成形术在临床实践过程中成为治疗 MCSM 最有效的方法之一<sup>[4-6]</sup>。高速磨钻是常用脊柱外科截骨工具,为了提高术中使用安全性和有效性,对高速磨钻进行了各种改进。然而,基于其本身



注:1a: X 线片示颈椎失稳;1b: MRI 示多节段脊髓型颈椎病;1c: CTA 示椎动脉结构;1d: 使用超声骨刀术中图片;1e ~ 1h: 术后 CT 示内固定满意。

图 1 典型病例 X 线片、MRI、CTA、术中图片及术后 CT 图

设计原理,通过物理磨削切除骨组织,不可避免会在使用过程中出现高温造成热灼伤、损伤邻近软组织、打滑等风险,而且传统高速磨钻学习曲线较长,对使用者要求高,稍有不慎,可能会导致脑脊液漏、神经根损伤、血管损伤等严重后果<sup>[7-9]</sup>。脊柱外科需要安全、有效、可控的截骨工具来完成一系列手术操作。

超声骨刀设计原理是在超声频率下的微振动来进行安全有效的截骨。它具有选择性的骨切割特性、保护相邻软组织、同时使用过程中不会产生高温、易于操控等特性。迄今为止,已在口腔、整形科广泛应用。大量报道显示出其与传统工具相比,具有软组织损伤小、术后水肿程度轻、疼痛更少等优势。其在手术操作精准及可控性方面远优于传统磨钻<sup>[10-12]</sup>。Bertossi 等<sup>[13]</sup>报道了超声骨刀应用于 55 例牙面部畸形矫治手术,取得了满意的效果,Koc 等<sup>[14]</sup>报道鼻截骨术中超声骨刀比常规截骨工具更加安全有效。

超声骨刀近年来开始在脊柱手术中应用。如李玉伟等<sup>[15]</sup>报道了超声骨刀应用于胸椎管肿瘤,He 等<sup>[16]</sup>报道了一例 27 岁肿瘤患者应用超声骨刀切除肿瘤,同时 3D 打印的钛微孔假体重建 C1 和 T1 之间的颈椎前柱,Liu 等<sup>[17]</sup>报道了超声骨刀应用于多节段胸椎黄韧带骨化治疗。以上均提示超声骨刀是一种有效、安全的工具。

本研究中,所有 MCSM 患者均采用超声骨刀进行单开门椎管扩大成形术,与术前相比,术后及末次随访时 JOA 评分均显著升高。且 32 例均未发现严重并发症,如脑脊液漏及神经根损伤等。MCSM 患者许多合并颈椎曲度改变,甚至出现较重的后凸畸形。利用侧块螺钉固定,置入的风险较小,对颈椎失稳能

达到即刻稳定效果,但因螺钉的生物力学局限性,很难恢复颈椎曲度。因此对于合并颈椎后凸患者,后路椎板成形长节段椎弓根螺钉固定不仅能稳定失稳椎体,而且能明显恢复颈椎曲度,为脊髓的后移制造空间,增加手术效果。Abumi 等<sup>[18]</sup>报道使用颈椎椎弓根系统对伴后凸畸形的颈椎病患者纠正达到平均 26.0°,可见椎弓根螺钉系统利用旋棒技术,能明显矫正颈椎后凸畸形。对于颈椎失稳但曲度正常的 MCSM,采用后路椎板成形椎弓根螺钉固定治疗方法,因椎弓根螺钉生物力学稳定性优于侧块螺钉,术中可短节段固定,不仅具有强大的复位能力,术后无需颈部外固定<sup>[19]</sup>。随访过程中通过 X 线、CT 检查显示螺钉位置良好,椎管扩大成形满意,无门轴断裂及再关门。超声骨刀应用于后路单开门椎管成形术治疗 MCSM 是一安全、有效的方法。可以预见,超声骨刀在 MCSM 等这类需要安全、可控截骨的脊柱手术中有广阔应用前景。

#### 参考文献

- [1] Mirza AA, Alandejani TA, Al-Sayed AA. Piezosurgery versus conventional osteotomy in rhinoplasty: a systematic review and meta-analysis [J]. *Laryngoscope*, 2019 November 22. [Epub ahead of print].
- [2] Keyhan SO, Fallahi HR, Cheshmi B, et al. Use of piezoelectric surgery and Er: YAG laser; which one is more effective during impacted third molar surgery? [J]. *Maxillofac Plast Reconstr Surg*, 2019, 41 (1):29.
- [3] Iwasaki M, Okuda S, Miyauchi A, et al. Surgical strategy for cervical myelopathy due to ossification of the posterior longitudinal ligament: Part 1: Clinical results and limitations of laminoplasty [J]. *Spine*, 2007, 32(6):647-653.
- [4] Hashimoto K, Aizawa T, Ozawa H, et al. Reoperation rates after

- laminoplasty for cervical disorders: a 26-year period survival function method analysis [J]. *Spine Surg Relat Res*, 2019, 3(4): 304 – 311.
- [5] 罗登科, 周纳新, 赵红卫, 等. 脊髓型颈椎病的影像学改变及治疗 [J]. *中国临床研究*, 2017, 30(2): 229 – 233.
- [6] Bajamal AH, Kim SH, Arifianto MR, et al. Posterior surgical techniques for cervical spondylotic myelopathy: WFNS spine committee recommendations [J]. *Neurospine*, 2019, 16(3): 421 – 434.
- [7] Kim CH, Chung CK, Choi Y, et al. The efficacy of ultrasonic bone scalpel for unilateral cervical open-door laminoplasty: a randomized controlled trial [J]. *Neurosurgery*, 2019; nyz301.
- [8] Pflugmacher R, Franzini A, Horovitz S, et al. Suitability of administrative databases for durotomy incidence assessment: comparison to the incidence associated with bone-removal devices, calculated using a systemic literature review and clinical data [J]. *Int J Spine Surg*, 2018, 12(4): 498 – 509.
- [9] Matthes M, Pillich DT, El Refaee E, et al. Heat generation during bony decompression of lumbar spinal stenosis using a high-speed diamond drill with or without automated irrigation and an ultrasonic bone-cutting knife: a single-blinded prospective randomized controlled study [J]. *World Neurosurg*, 2018, 111: e72 – e81.
- [10] Ribeiro Scheffer MA, Bon AM, Tochetto Primo B, et al. Surgical treatment of condylar hyperplasia associated with dentofacial deformity using piezosurgery [J]. *J Stomat Occ Med*, 2016, 8 ( S1 ): 65 – 71.
- [11] Pakhare V, Khandait C, Shrivastav S, et al. Piezosurgery<sup>®</sup>-assisted periodontally accelerated osteogenic orthodontics [J]. *J Indian Soc Periodontol*, 2018, 21(5): 422 – 426.
- [12] Koçak I, Doğan R, Gökler O. A comparison of piezosurgery with conventional techniques for internal osteotomy [J]. *Eur Arch Otorhinolaryngol*, 2017, 274(6): 2483 – 2491.
- [13] Bertossi D, Albanese M, Mortellaro C, et al. Osteotomy in genioplasty by piezosurgery [J]. *J Craniofac Surg*, 2018, 29(8): 2156 – 2159.
- [14] Koc B, Koc EA, Erbek S. Comparison of clinical outcomes using a Piezosurgery device vs. a conventional osteotome for lateral osteotomy in rhinoplasty [J]. *Ear Nose Throat J*, 2017, 96(8): 318 – 326.
- [15] 李玉伟, 王海蛟, 崔巍, 等. 应用超声骨刀行改良棘突椎板韧带复合体回植术治疗胸椎管内良性肿瘤 [J]. *中国修复重建外科杂志*, 2019, 33(8): 991 – 995.
- [16] He SH, Yang XH, Yang J, et al. Customized “whole-cervical-vertebral-body” reconstruction after modified subtotal spondylectomy of C2-C7 spinal tumor via piezoelectric surgery [J]. *Oper Neurosurg (Hagerstown)*, 2019, 17(6): 580 – 587.
- [17] Liu XW, Li TF, Shi L, et al. Application of piezosurgery in en bloc laminectomy for the treatment of multilevel thoracic ossification of ligamentum flavum [J]. *World Neurosurg*, 2019, 126: 541 – 546.
- [18] Abumi K, Shono Y, Taneichi H, et al. Correction of cervical kyphosis using pedicle screw fixation systems [J]. *Spine*, 1999, 24 ( 22 ): 2389 – 2396.
- [19] 谢守宁, 韩生寿, 李洪. 颈椎椎弓根螺钉固定联合椎板成形术治疗不稳定性脊髓型颈椎病 [J]. *中国矫形外科杂志*, 2013, 21 ( 15 ): 1572 – 1575.

收稿日期: 2019 – 12 – 01 修回日期: 2020 – 03 – 13 编辑: 王宇

(上接第 817 页)

- [7] Ryu MH, Kang YK. MLI7032 trial: capecitabine/cisplatin versus 5-fluorouracil/cisplatin as first-line therapy in advanced gastric cancer [J]. *Expert Rev Anticancer Ther*, 2009, 9(12): 1745 – 1751.
- [8] Lv F, Liu X, Wang BY, et al. S-1 monotherapy as second line chemotherapy in advanced gastric cancer patients previously treated with cisplatin/infusional fluorouracil [J]. *Int J Clin Exp Pathol*, 2014, 7 ( 7 ): 4274 – 4279.
- [9] Wang Y, Zhuang RY, Yu YY, et al. Efficacy of preoperative chemotherapy regimens in patients with initially unresectable locally advanced gastric adenocarcinoma: capecitabine and oxaliplatin (XELOX) or with epirubicin (EOX) [J]. *Oncotarget*, 2016, 7 ( 46 ): 76298 – 76307
- [10] Goto Y, Wakita S, Yoshimitsu M, et al. Onset of syndrome of inappropriate secretion of antidiuretic hormone in a gastric cancer patient on SOX treatment [J]. *Gan To Kagaku Ryoho*, 2015, 42 ( 13 ): 2467 – 2470.
- [11] 杨武, 喻永龙, 朱西平, 等. 替吉奥和卡培他滨分别联合奥沙利铂化疗对晚期胃癌疗效观察 [J]. *蚌埠医学院学报*, 2014, 39 ( 11 ): 1512 – 1514.
- [12] 姚荣杰, 孟曼, 丁露, 等. 卡培他滨联合奥沙利铂方案与替吉奥联合奥沙利铂方案治疗晚期胃癌的近期疗效与安全性比较 [J]. *黑龙江医学*, 2017, 41(8): 776 – 777.
- [13] 王冠青, 韩雅琳, 陈丽, 等. 奥沙利铂联合卡培他滨辅助化疗方案对Ⅲ期胃癌术后患者的疗效分析 [J]. *解放军医学院学报*, 2019, 40(3): 227 – 230.
- [14] 陈华敏, 吴煌福, 黄光钺. 卡培他滨辅助化疗治疗老年晚期胃癌 50 例疗效评价 [J]. *中国药业*, 2018, 27(7): 44 – 46.
- [15] 时华. 奥沙利铂 + 替吉奥化疗方案在老年胃癌治疗中的应用效果观察 [J]. *临床医药文献电子杂志*, 2018, 5(A4): 160, 170.
- [16] 黄贵卿. 卡培他滨治疗老年胃肿瘤的临床效果研究 [J]. *中国医药指南*, 2019, 17(10): 58 – 59.
- [17] Qiu MZ, Cai MY, Zhang DS, et al. Clinicopathological characteristics and prognostic analysis of Lauren classification in gastric adenocarcinoma in China [J]. *J Transl Med*, 2013, 11: 58.
- [18] 曹文君, 李敏, 李慧娟. 肠型胃癌和弥漫型胃癌的临床特点及预后研究 [J]. *中国全科医学*, 2017, 20(13): 1587 – 1591.
- [19] 朱志, 王振宁. 胃癌腹膜转移的诊治研究进展 [J]. *实用肿瘤杂志*, 2018, 33(3): 204 – 208.
- [20] Ito S, Ohashi Y, Sasako M. Survival after recurrence in patients with gastric cancer who receive S-1 adjuvant chemotherapy: exploratory analysis of the ACTS – GC trial [J]. *BMC Cancer*, 2018, 18: 449.

收稿日期: 2019 – 09 – 09 编辑: 王娜娜